

人工智能辅助诊断系统在新型冠状病毒肺炎诊断中的初步应用

邓灵波¹, 周雯¹, 赵双全², 向子云³, 成官迅¹

1. 北京大学深圳医院医学影像科, 广东 深圳 518036; 2. 深圳市宝安区人民医院影像科, 广东 深圳 518101; 3. 深圳市龙岗区人民医院影像科, 广东 深圳 518172

【摘要】目的:评估人工智能(AI)辅助诊断系统对新型冠状病毒肺炎(NCIP)的诊断价值。**方法:**回顾性分析26例NCIP患者的临床资料与CT图像。利用AI系统新冠肺炎诊断模块自动识别肺炎病变的数量、测量病变体积、计算病变体积所占肺叶的百分比,得出病变的疑似新冠肺炎的概率。评估该AI系统识别病变数量的准确性和病变范围的准确性。**结果:**26例NCIP患者AI自动检测出215处病变,其中76.9%(20/26)的患者AI识别的病变数量高于医生评估的数量。23.1%(6/26)的患者病变体积小于10 cm³,38.5%(10/26)的患者病变体积为10~100 cm³,38.5%(10/26)的患者病变体积大于100 cm³。57.7%(15/26)的患者病变体积百分比小于10%,23.1%(6/26)的患者体积百分比为10%~25%,15.4%(4/26)的患者体积百分比为25%~50%,3.8%(1/26)的患者体积百分比大于50%。34.6%(9/26)的患者NCIP的疑似概率大于50%,其中仅11.5%(3/26)的患者疑似概率为99%,65.4%(17/26)的患者疑似概率小于25%。61.5%(16/26)的患者肺部一些较小的病变未被AI识别,38.5%(10/26)的患者两个相邻病变识别为同一病变,42.3%(11/26)的患者肺部伪影被识别为病变,61.5%(16/26)的患者肺部正常结构被识别为病变,30.8%(8/26)的患者肺内的一些其他病灶被识别为NCIP病变,46.2%(12/26)的患者小病灶被识别为肺结节。88.5%(23/26)的患者部分病变边缘正常的肺组织被识别为病变;61.5%(16/26)的患者部分病变边缘未被识别为病变。**结论:**AI辅助诊断系统能迅速识别CT影像中的肺炎病变,并进行体积测量,给出NCIP的疑似概率,帮助医生快速识别高危人群,判断病情的严重程度以及疗效,节省时间和精力,达到精准防控的效果。

【关键词】新型冠状病毒肺炎;X线计算机体层摄影术;人工智能;辅助诊断

【中图分类号】R318;R563.1

【文献标志码】A

【文章编号】1005-202X(2020)12-1604-05

Preliminary application of AI diagnosis system in the diagnosis of the novel coronavirus infected pneumonia

DENG Lingbo¹, ZHOU Wen¹, ZHAO Shuangquan², XIANG Ziyun³, CHENG Guanxun¹

1. Department of Medical Imaging, Shenzhen Hospital of Peking University, Shenzhen 518036, China; 2. Department of Radiology, Baoan People's Hospital, Shenzhen 518101, China; 3. Department of Radiology, Longgang People's Hospital, Shenzhen 518172, China

Abstract: Objective To evaluate the diagnostic value of artificial intelligence (AI) assisted diagnosis system for new coronavirus pneumonia (NCIP). **Methods** The clinical data and CT images of 26 NCIP patients were retrospectively analyzed. The new coronary pneumonia diagnosis module of the AI system is used to automatically identify the number of pneumonia lesions, measure the volume of the lesion, and calculate the percentage of the lesion volume in the lung lobe to obtain the probability of suspected new coronary pneumonia. Evaluate the accuracy of the AI system in identifying the number of lesions and the accuracy of the scope of the lesion. **Results** The AI system automatically detected 215 lesions of 26 NCIP patients. In 76.9% (20/26) of the patients AI has recognized more lesions than the doctor did. 23.1% (6/26) of the patients had a lesion volume less than 10 cm³, 38.5% (10/26) had a lesion volume of 10-100 cm³, and 38.5% (10/26) had a lesion volume greater than 100 cm³. 57.7% (15/26) patients have lesion volume percentage less than 10%, 23.1% (6/26) patients have a volume percentage of 10%~25%, 15.4% (4/26) patients have a volume percentage of 25%~50%, and only 3.8% (1/26) of the patient have a volume percentage greater than 50%. 34.6% (9/26) patients have a suspected probability of NCIP greater than 50%, of which only 11.5% (3/26) patients have a suspected probability of 99%, and 65.4% (17/26) patients have a suspected probability of less than 25%. 61.5% (16/26) of the patients have some smaller lesions unrecognized by AI, 38.5% (10/26) of the patients have two adjacent lesions that was mistakenly recognized

【收稿日期】2020-07-18

【基金项目】广东省自然科学基金(S2011010003870);深圳市卫健委学科建设能力提升项目(SZXJ2018076)

【作者简介】邓灵波, 硕士, 主治医师, 研究方向: 人工智能在影像诊断中的应用, E-mail: denglingbo1@126.com

【通信作者】成官迅, 博士, 教授, 研究方向: 影像诊断, E-mail: 18903015678@189.cn

as the same lesion, and there are also 42.3% (11/26) of the patients whose lungs partial artifacts were identified as lesions, 61.5% (16/26) of the patients whose normal lung structures were identified as lesions, 30.8% (8/26) of the patients' whose lungs were identified as NCIP lesions, and 46.2% (12/26) of the patients whose small lesions were identified as lung nodules. In 88.5% (23/26) patients, some lung tissues with normal edges of the lesion were recognized as lesions; in 61.5% (16/26) of the patients the lesion edge was not recognized. **Conclusion** The AI-assisted diagnosis system can quickly identify pneumonia lesions in CT images, and measure the volume, give the suspected probability of NCIP, help doctors quickly identify high-risk groups, determine the severity and efficacy of the disease, save time and energy, and achieve precise prevention and control Effect.

Keywords: novel coronavirus infected pneumonia; computed tomography; artificial intelligence; diagnosis system

前言

WHO将自2019年12月起流行的新型冠状病毒命名为严重急性呼吸综合征冠状病毒2(severe acute respiratory syndrome coronavirus 2, SARS-CoV-2),该病毒感染人类引起的疾病命名为2019冠状病毒病(coronavirus disease 2019, COVID-19)^[1]。由新型冠状病毒感染引起的以肺部炎症为主的疾病被称为新型冠状病毒肺炎(novel coronavirus infected pneumonia, NCIP)^[2-3]。胸部CT检查能够快速了解肺部情况,达到早诊断、早隔离、早治疗以及评价疗效的作用。随着疫情进展,越来越多的人需要进行胸部CT筛查以排除是否存在NCIP^[4-6],影像科医师阅片工作量大幅增加。人工智能(AI)计算机辅助诊断系统作为处理影像数据的有效辅助工具,可以协助医生发现、识别病变,估算病变范围,在随访中能够定量评估病变密度和范围变化,客观评估治疗效果,为临床治疗方案的选择提供依据^[7-8]。本研究通过评估AI计算机辅助诊断系统对NCIP病灶的检出、测量及分析能力,探讨该系统对NCIP的诊断价值。

1 资料与方法

1.1 研究对象

回顾性收集2020年1月至4月就诊于北京大学深圳医院门诊,且按国家卫生健康委员会规定的《新型冠状病毒感染的肺炎诊疗方案(试行第7版)》^[9]诊断为COVID-19患者26例;其中男14例,女12例;年龄16~70岁,平均年龄52.7岁。所有患者的咽拭子标本均经逆转录-聚合酶链反应(RT-PCR)检测SARS-CoV-2核酸阳性,并在我院行胸部CT检查,我院PACS系统内存有完整的CT图像,且拥有完整的薄层重建图像,重建层厚≤1 mm。

1.2 仪器与方法

胸部CT检查采用Anke Anatom 64 CT机进行扫描。患者取仰卧位,头先进,双臂上举,扫描范围从肺尖至肺底,两侧包括胸壁、腋窝。扫描参数:管电压100~120 kV,自动管电流调制技术,管电流50~

200 mA,转速0.4 s/r,螺距0.938。准直层厚0.625×32排。肺窗窗位-600~-450 HU,窗宽1 000~1 500 HU,纵隔窗窗位35~40 HU,窗宽300~350 HU。重建层厚5 mm的肺窗和纵隔窗图像进行病变观察,再重建层厚0.625 mm的高分辨肺窗图像进行进一步观察,将0.625 mm的高分辨肺窗图像上传至医准智能辅助诊断系统进行分析。

1.3 图像分析

使用AI系统的肺炎辅助诊断模块进行病变的定量研究与观察评估。该系统能够自动识别病变的数量,测量病变体积,计算病变体积所占肺叶的百分比,得出病变NCIP的疑似概率。

1.4 判定标准

由2名诊断经验丰富的高年资放射科医师分别采用盲法独立阅片。医生主要评价的内容包括:(1)患者肺炎病变的数量。(2)AI系统识别肺炎病变数量的准确性,其中包括:是否存在较小的病变未识别;是否两个相邻病变识别为同一病变;是否部分移动伪影被识别为病变;是否部分正常结构被识别为病变;是否其他病变被识别为肺炎;是否肺炎被识别为其他病变。(3)AI系统识别肺炎病变范围的准确性:是否部分病变边缘正常的肺组织被识别为病变,导致病变识别范围增大;是否部分病变边缘未被识别为病变,导致病变识别范围减小。典型病例资料见图1和图2。

2 结果

2.1 AI系统对NCIP病变数量的显示情况

26例NCIP患者经过医师鉴别出的病变为169处,而AI自动检测出215处病变,其中7例患者病变数量大于等于10处,余19例病变数量小于10处。其中3例患者AI识别的病变数量小于医师识别的数量,3例患者AI和医生识别的病变数量相同,余20例患者AI识别出的病变数量均大于医生识别的数量。

2.2 AI系统对NCIP病变体积的显示情况

AI能够自动识别每位患者每个病变的体积,其中6例患者病变体积小于10 cm³,10例患者病变体积

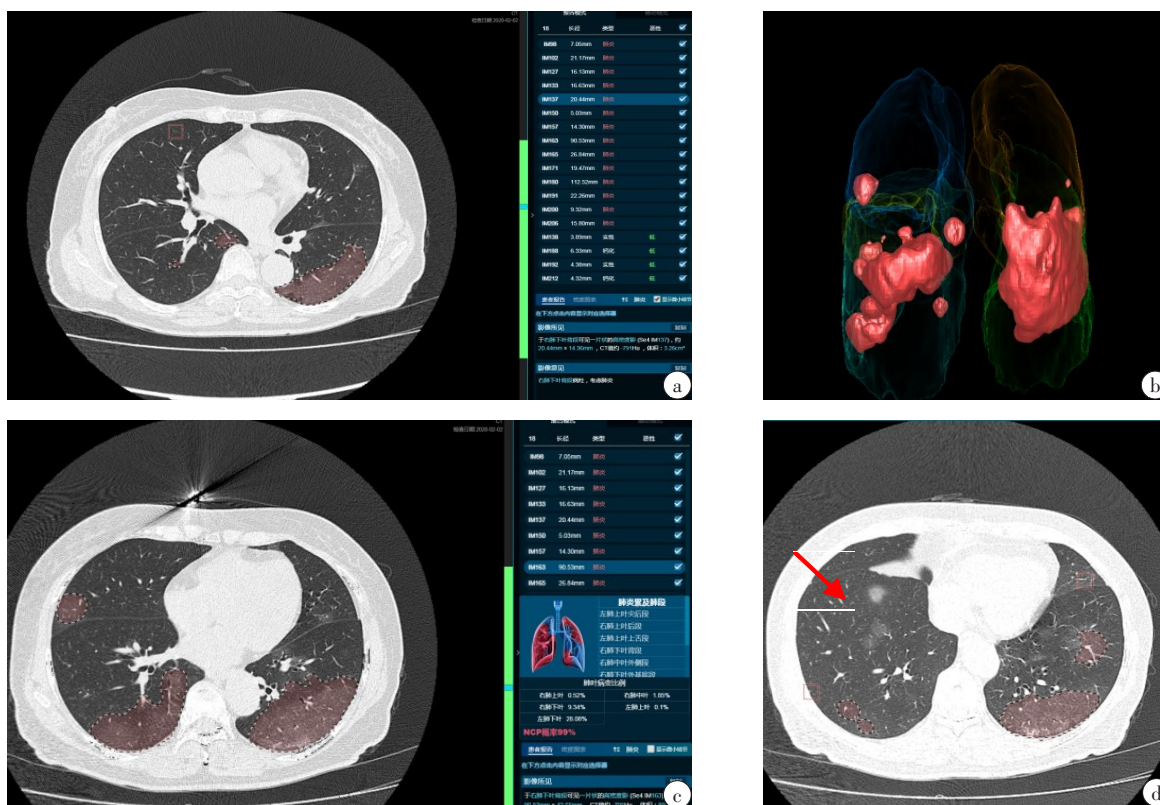


图1 女,65岁,2020年1月22日去新加坡旅游,27日回深圳,近5 d发热,体温达38.8℃,伴胸闷、周身酸痛、流涕、咳嗽、咳黄痰,2020-2-2行胸部CT检查

Fig.1 Female, 65 years old, who went to Singapore on January 22, 2020 and returned to Shenzhen on January 27. She had a fever in the past five days, with a temperature of 38.8 degrees, chest tightness, body pain, runny nose, cough and yellow phlegm. Chest CT was performed on February 2, 2020.

a:AI识别患者有14处肺炎病变,可以在横截面上测量每个肺炎病变的大小;b:三维图像显示病变累及肺叶情况;c:AI自动计算每个肺叶病变所占体积比,测算出NCIP的疑似概率为99%;d:对于部分小病灶(箭头),AI未能识别

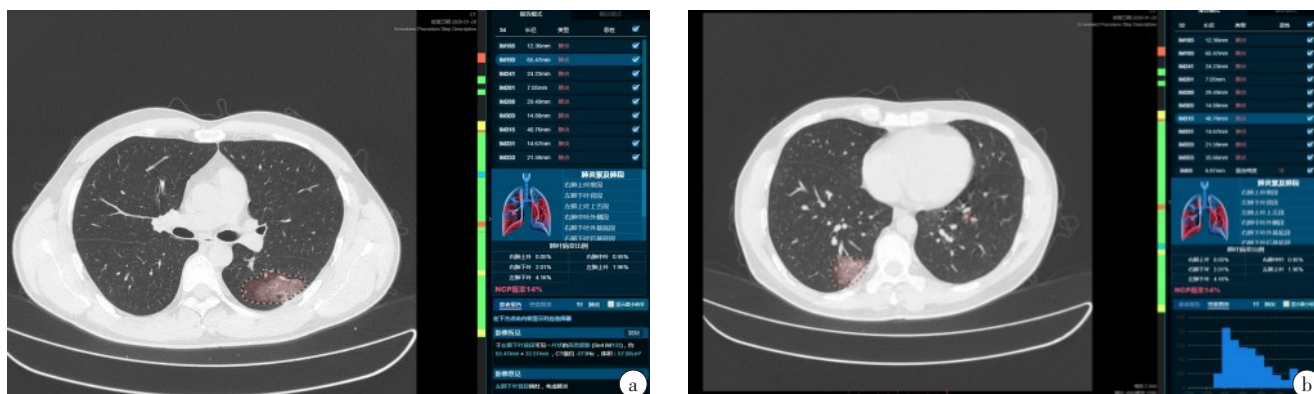

图2 男,45岁,2020年1月10日离开武汉来深圳,近3 d发热,体温达37.6℃,伴咽痒、鼻塞、咳嗽、干咳、腹泻、无胸闷,2020-1-28行胸部CT检查

Fig.2 Male, 45 years old, whocame from Wuhanto Shenzhen on January 10, 2020. He had a fever for nearly three days, with a temperature of 37.6 degrees. He had itchy throat, stuffy nose, cough, dry cough, diarrhea and no chest tightness. Chest CT was performed on January 28, 2020.

a:AI识别患者NCIP的疑似概率为14%,病灶边缘部分正常的肺组织被识别;b:AI计算每个病变内密度分布直方图

为10~100 cm³,10例患者病变体积大于100 cm³。AI能够计算出病变体积占整个肺部体积的百分比,15例患者病变体积百分比小于10%,6例患者病变体积百分比为10%~25%,4例患者病变体积百分比为25%~50%,1例患者病变体积百分比大于50%。

2.3 AI系统对NCIP病变的疑似概率的评估

26例患者中9例患者NCIP的疑似概率大于50%,17例患者的NCIP疑似概率小于25%。26例NCIP患者中仅3例患者AI评估的疑似概率为99%。

2.4 评估AI系统识别病变数量的准确性

26例患者中16例患者存在一些较小的病变未被识别;10例患者存在两个相邻病变识别为同一病变的情况,11例患者一些心脏的移动伪影、膈肌运动伪影及呼吸移动伪影被认为是病变,16例患者一些正常结构如支气管、血管、肺门等被识别为较小的病变,8例患者一些肺内的纤维灶、钙化灶及结节被认为是NCIP病变,12例患者NCIP病灶被识别为肺结节。

2.5 评估 AI 系统勾画 NCIP 病变范围的准确性

23例患者存在部分NCIP病变边缘正常的肺组织被识别为病变,导致AI识别病变体积增大;16例患者部分病变边缘未被识别为病变,导致AI识别病变体积减小。

3 讨论

COVID-19属于国家“乙类”传染病,采取“甲类”传染病防控措施。感染主要为飞沫和近距离接触传播,可经人与人传播,人群普遍易感,且重症病例死亡率高。随着疫情发展,一些研究表明COVID-19有可能转成慢性,像流感一样长期在人间存在,潜在的风险可能是长期和巨大的,对此要做好准备。COVID-19的筛查要成为一项医院的标准流程。因此,建立快速诊断COVID-19能力非常重要。患者咽拭子标本均经逆转录-聚合酶链反应(RT-PCR)检测阳性,是诊断COVID-19的“金标准”。核酸检测试剂盒有限并且所需检查时间较长,另外目前核酸检测大部分标本采用咽拭子,未广泛使用肺泡灌洗液,所以核酸检测存在一定的假阴性^[10-11]。高分辨率CT扫描能准确观察到次级肺小叶等肺组织细微结构,并能发现肺部磨玻璃密度影及网格状阴影等细微病变,所以推荐高分辨率CT扫描作为临床早期筛查患者的重要手段之一。

由于CT能提供海量的薄层断层图像,人工阅片耗时较长,增加了影像医生的工作负担。近年来AI在肺结节检出方面得到广泛运用,大大提高了检出率,减少了结节的漏诊。疫情期间,AI在诊断NCIP方面也取得了一定发展,其可以帮助医生迅速识别CT影像中的NCIP病变,进行病灶轮廓的分割、体积测量,还可以进行随访对比,从而可以使医生快速精准地判断病情的严重程度及疗效,节省时间与精力^[12]。由于NCIP患者CT表现的特异性,AI有望通过深度学习,为与其它病毒性肺炎的鉴别诊断提供依据^[13-14]。

随着计算机技术的飞速发展,肺结节智能辅助诊断系统在诊断肺结节方面已日趋成熟,且具有较

高的敏感性,但特异性较低。目前主要作为影像诊断的辅助工具,尚不能完全替代影像医生用于临床。新冠肺炎疫情期间,多家公司推出了新冠肺炎CT影像辅助诊断的AI系统,能够自动识别病变数量、定位病变,给出病变累及的肺段,测量病变长径、最大截面积、平均CT值,给出病变CT密度分布的直方图,勾画病变轮廓,测量病变体积,计算病变所占肺叶的百分比,并给出NCIP的疑似概率,还可以进行病变的随访对比^[15-16]。帮助医生快速了解病变累及的范围,判断病变严重程度,通过随访定量的评估病变范围及密度的变化,更精确地判断疗效。典型NCIP的CT表现具有一定的特异性^[17-19],通过AI能够给出新冠肺炎的疑似概率,快速识别高危人群,达到精准防控的效果^[20]。

本研究结果显示该AI系统对于NCIP诊断有一定价值,能够测量病变体积,计算病变体积百分比,给出疑似概率。本研究76.9%的病例AI识别病变数量高于医生识别的数量,主要原因是一些伪影如心脏移动伪影、膈肌运动伪影及呼吸移动伪影,一些正常结构如支气管、血管、肺门,一些肺内的纤维灶、钙化灶及结节被识别为NCIP病变。本研究仅有11.5%的病例AI识别NCIP的疑似概率为99%,仅34.6%的病例AI识别NCIP的疑似概率大于50%,65.4%的病例NCIP的疑似概率小于25%。AI对于NCIP判断的准确性存在一定差异,需要进一步研究。88.5%的病例AI系统将NCIP病变边缘正常的肺组织被识别为病变,导致病变勾画范围增大,61.5%的病例部分病变边缘未被识别为病变,导致病变勾画范围减小,影响病变体积的计算。

本研究的局限性:(1)本研究是回顾性分析,纳入的例数较少,且只是患者第一次在我院的检查影像,可能存在一定的选择性偏倚;(2)本研究病变的体积是由AI测量所得,没有进行人工测量,可能存在一定误差;(3)本研究对于AI诊断NCIP的评价大部分是一些等级指标,没有进行精确比较。

综上所述,AI可以帮助医生迅速识别CT影像中的COVID-19病变,并进行体积测量,快速精准地判断病情的严重程度及疗效,从而节省时间和精力。典型的NCIP的CT表现具有一定特异性,通过AI能够给出NCIP的疑似概率,快速识别高危人群,达到精准防控的效果,但AI对于NCIP疑似概率判断的准确性有待进一步提高。

【参考文献】

[1] World Health Organization. Clinical management of severe acute

- respiratory infection when novel coronavirus (nCoV) infection is suspected: interim guidance [EB/OL]. [https://www.who.int/internal-publications-detail/clinical-management-of-severe-acute-respiratory-infection-when-novel-coronavirus-\(ncov\)-infection-is-suspected](https://www.who.int/internal-publications-detail/clinical-management-of-severe-acute-respiratory-infection-when-novel-coronavirus-(ncov)-infection-is-suspected) (accessed Jan 20, 2020).
- [2] WANG D, HU B, HU C, et al. Clinical characteristics of 138 hospitalized patients with 2019 novel coronavirus-infected pneumonia in Wuhan, China [J]. JAMA, 2020, 323(11): 1061.
 - [3] CHEN N, ZHOU M, DONG X, et al. Epidemiological and clinical characteristics of 99 cases of 2019 novel coronavirus pneumonia in Wuhan, China: a descriptive study [J]. Lancet, 2020, 395(10223): 507-513.
 - [4] LI M, LEI P, ZENG B, et al. Coronavirus disease (COVID-19): spectrum of CT findings and temporal progression of the disease [J]. Acad Radiol, 2020, 27(5): 603-608.
 - [5] 史河水, 韩小雨, 樊艳青, 等. 新型冠状病毒(2019-nCoV)感染的肺炎临床特征及影像学表现 [J]. 临床放射学杂志, 2020, 39(1): 8-11. SHI H S, HAN X Y, FAN Y Q, et al. Radiologic features of patients with 2019-nCoV infection [J]. Journal of Clinical Radiology, 2020, 39(1): 8-11.
 - [6] 吴玉锦, 王希明, 胡春洪. 新型冠状病毒肺炎的CT表现初探 [J]. 实用放射学杂志, 2020, 36(4): 520-522. WU Y J, WANG X M, HU C H. Preliminary CT findings of COVID-19 [J]. Journal of Practical Radiology, 2020, 36(4): 520-522.
 - [7] WU X, HUI H, NIU M, et al. Deep learning-based multi-view fusion model for screening 2019 novel coronavirus pneumonia: a multicentre study [J]. Eur J Radiol, 2020, 128: 109041.
 - [8] RUECKEL J, KUNZ W G, HOPPE B F, et al. Artificial intelligence algorithm detecting lung infection in supine chest radiographs of critically ill patients with a diagnostic accuracy similar to board-certified radiologists [J]. Crit Care Med, 2020, 48(7): e574-e583.
 - [9] 中华人民共和国国家卫生健康委员会. 新型冠状病毒感染的肺炎诊疗方案(试行第七版) [EB/OL]. <http://www.nhc.gov.cn/xcs/zhengcwj/202003/46c9294a7dfe4cef80dc7f5912eb1989.shtml>. National Health and Health Commission of the people's Republic of China. Diagnosis and treatment of novel coronavirus infection pneumonia (trial version 7) [EB/OL]. <http://www.nhc.gov.cn/xcs/zhengcwj/202003/46c9294a7dfe4cef80dc7f5912eb1989.shtml>.
 - [10] AI T, YANG Z, HOU H, et al. Correlation of chest CT and RT-PCR testing in coronavirus disease 2019 (COVID-19) in China: a report of 1 014 cases [J]. Radiology, 2020: 200642.
 - [11] FANG Y, ZHANG H, XIE J, et al. Sensitivity of chest CT for COVID-19: comparison to RT-PCR [J]. Radiology, 2020: 200432.
 - [12] MURPHY K, SMITS H, KNOOPS A, et al. COVID-19 on the chest radiograph: a multi-reader evaluation of an AI system [J]. Radiology, 2020: 201874.
 - [13] BIEN N, RAJPURKAR P, BALL R, et al. Deep-learning-assisted diagnosis for knee magnetic resonance imaging: Development and retrospective validation of MRNet [J]. PLoS Med, 2018, 15(11): e1002699.
 - [14] RAJARAMAN S, ANTANI S. Weakly labeled data augmentation for deep learning: a study on COVID-19 detection in chest X-rays [J]. Diagnostics, 2020, 10(6): 358.
 - [15] LI L, QIN L, XU Z, et al. Artificial intelligence distinguishes COVID-19 from community acquired pneumonia on chest CT [J]. Radiology, 2020: 200905.
 - [16] BAI H, WANG R, XIONG Z, et al. AI augmentation of radiologist performance in distinguishing COVID-19 from pneumonia of other etiology on chest CT [J]. Radiology, 2020: 201491.
 - [17] 周洁, 马婉玲, 靳晓军, 等. 新型冠状病毒肺炎的影像学征象初探 [J]. 实用放射学杂志, 2020, 36(4): 523-525. ZHOU J, MA W L, JIN X J, et al. Preliminary study of the imaging features of COVID-19 [J]. Journal of Practical Radiology, 2020, 36(4): 523-525.
 - [18] LIU F, ZHANG Q, HUANG C, et al. CT quantification of pneumonia lesions in early days predicts progression to severe illness in a cohort of COVID-19 patients [J]. Theranostics, 2020, 10(12): 5613-5622.
 - [19] 杜永浩, 金晨望, 杨健, 等. 家庭聚集性早期新型冠状病毒肺炎的临床与CT表现的初步探讨 [J]. 西安交通大学学报(医学版), 2020, 41(3): 435-438.
 - [20] DU Y H, JIN C W, YANG J, et al. Clinical features and CT signs of early family clustering corona virus disease 2019 [J]. Journal of Xi'an Jiaotong University (Medical Sciences), 2020, 41(3): 435-438.
 - [20] COLOMBI D, BODINI F C, PETRINI M, et al. Well-aerated lung on admitting chest CT to predict adverse outcome in COVID-19 pneumonia [J]. Radiology, 2020: 201433.

(编辑:黄开颜)